

# Anaesthesia for Thoracic Aortic Disease: Series of Four Cases

S AJANTH<sup>1</sup>, S MANO PRAVEEN<sup>2</sup>, RAMESHWAR A MHAMANE<sup>3</sup>, CHARULATA M DESHPANDE<sup>4</sup>

## ABSTRACT

Thoracic aortic diseases involving the thoracic aorta, from the ascending aorta, the aortic arch to the descending aorta, can present in the form of aneurysms, dissection, tear and coarctation which usually lead to various complications, requiring surgical intervention. The same can be addressed surgically by ascending aorta replacement or reduction aortoplasty with/without Aortic Valve Replacement (AVR). The anaesthetic implications might vary depending on the pathology of the thoracic aortic disease which can be acute or chronic and, silent or symptomatic. Anaesthetic management of four patients (1 female and 3 males) with varied thoracic aortic diseases have been described in the series, including bicuspid aortic valve with severe aortic stenosis, Ischaemic Heart Disease (IHD) with severe Aortic Regurgitation (AR) with ascending aortic aneurysm, ascending aortic dilatation in a known Takayasu arteritis patient and coarctation of aorta with atrial septal defect. These patients underwent aortoplasty with or without aortic root replacement. Full cardiopulmonary bypass with Deep Hypothermic Circulatory Arrest (DHCA) at 16-20°C was the technique used for these procedures as it prevents stroke and ensures cognitive function. This technique had no additional cannulas, less chances of intimal injury or embolisation and clear surgical fields. During the process of rewarming, Inj. Nitroglycerine was started which reduced preload, conserving the myocardium against ischaemic injuries. These patients were successfully managed perioperatively and were discharged with good outcomes postoperatively.

**Keywords:** Aortic aneurysms, Aortic stenosis, Bicuspid aortic valve, Coarctation of aorta

## INTRODUCTION

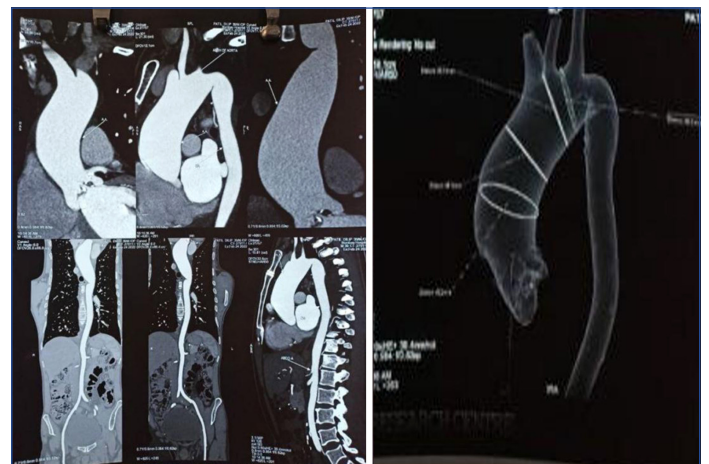
The spectrum of the thoracic aortic diseases diversifies from aortic aneurysms, acute aortic syndrome including aortic dissection, penetrating atherosclerotic ulcer, aortic rupture, inflammatory conditions, genetic diseases like Marfan syndrome and congenital abnormalities like coarctation of aorta. Thoracic aortic aneurysms are one of the most common thoracic aortic diseases and usually caused by degenerative changes, developing a dilatation in the aorta, where the incidence is around 10.4 per 100,000 person per year [1]. The risk factors for the same include smoking, coronary artery disease, hypertension, chronic obstructive pulmonary disease, various genetic conditions like Marfan's syndrome, Ehlers-Danlos syndrome, Turner's syndrome, and inflammatory conditions like Takayasu arteritis and giant cell arteritis [2]. Congenital bicuspid aortic valve is generally associated with aortic aneurysm, presenting in 1-2% of the population [3]. Coarctation of aorta accounting for 5-10% of congenital heart defects, is a narrowing of the aorta which occurs at the junction of descending aorta and arch of aorta distal to the left Subclavian Artery (SCA) [4]. Classically, aortic root replacement, AVR and reimplantation of the coronary buttons are done in Bentall procedure. However, various modifications of Bentall procedure have been studied as well. Alternatively, aortoplasty is done in certain conditions, which is less radical and an acceptable alternative with comparably good postoperative and long-term outcomes to the classical ascending aorta replacement with a graft [5]. The anaesthetic management in the thoracic aortic disease is complicated by perioperative stroke and spinal cord ischaemic injury, acute renal failure, myocardial ischaemia, arrhythmias and limb ischaemia, which requires the optimal preoperative assessment, planning, meticulous perioperative anaesthetic management.

## CASE SERIES

### CASE 1

A 39-year-old female presented to the Cardiothoracic and vascular outpatient Department with the history of syncope since

1 year. On systemic examination, S1S2 along with a systolic murmur over right sternal border at second intercostal space. It was a case of bicuspid aortic valve with severe aortic stenosis posted for AVR with aortoplasty [Table/Fig-1].



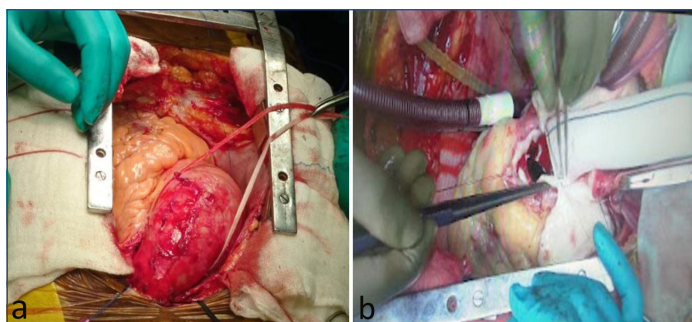
**[Table/Fig-1]:** The image showing the Computed Tomography (CT) aortogram depicting a bicuspid aortic valve with fusiform dilatation of ascending and arch of aorta in case 1.

### Case 2

A 55-year-old male presented to the Cardiothoracic and vascular outpatient Department with the history of dyspnoea since 6-7 years. On systemic examination, S1S2 along with a diastolic murmur over right sternal border at second intercostal space. It was a case of ischaemic heart disease- Chronic Stable Angina (CSA) with severe AR with ascending aorta aneurysm posted for Coronary Artery Bypass Graft (CABG) with AVR and aortic root replacement [Table/Fig-2].

### Case 3

A 39-year-old female presented to the Cardiothoracic and vascular outpatient Department with the history of chest pain and dyspnoea on exertion since 2 years. On systemic examination, S1S2 along with



**[Table/Fig-2]:** a) Fusiform dilatation of ascending aorta. b) Gel weave synthetic aortic graft in the ascending aorta for aortic root replacement in case 2. (Images from left to right).

a diastolic murmur over right sternal border at second intercostal space. It was a case of severe AR with ascending aortic dilatation in a patient of Takayasu arteritis posted for AVR with aortoplasty.

#### Case 4

A 26-year-old male presented to the Cardiothoracic and vascular outpatient Department with the history of dyspnoea on exertion since 2 years. On systemic examination, S1S2 along with no murmur. It was a case of coarctation of aorta with Atrial Septal Defect (ASD) for repair with prosthetic graft and ASD closure [Table/Fig-3].

#### Anaesthetic Management

Patients were evaluated thoroughly during the preoperative visit and counselled. On the day of surgery, fasting was confirmed

and high-risk informed consent was taken. 18 or 20 Gauge (G) peripheral intravenous access was taken in the right upper limb and premedicated with Inj. Fentanyl 1-2 mcg/kg. Right internal jugular 7 French (Fr) Central Venous Catheter (CVC) line and right femoral 4 or 5 Fr. Arterial line were taken under local anaesthesia with Ultrasonography (USG) guidance. The standard monitoring included pulse oximetry, Electrocardiography (ECG), invasive blood pressure, central venous pressure, capnography, neuromuscular monitoring, entropy, temperature and urine output. Activated Clotting Time (ACT), haemogram, ionogram, blood glucose and serial arterial blood gases were done. Induction was done with Inj. Midazolam 0.03-0.05 mg/kg, Inj. Fentanyl 5-8 mcg/kg, Inj. Etomidate 0.3-0.5 mg/kg and relaxation was achieved with Inj. Atracurium 0.5 mg/kg; maintenance was done with oxygen: Air (60:40): Sevoflurane (1-2%). Intraoperatively, sedation mixture of Inj. Propofol and Inj. Atracurium was started, titrated as per neuromuscular and entropy monitors and continued during Cardiac Pulmonary Bypass (CPB). Inj. unfractionated heparin 300U/kg was given before cannulation and ACT was targeted above 400 seconds.

Repair was done with use of full CPB with deep hypothalamic circulatory arrest. In the Institute, the heart was accessed by a median sternotomy and CPB initiation via cannulation in the ascending aorta or proximal aortic arch. During aortic cross-clamp, an umbilical tape was used to lift the ascending aorta and ensured that, the clamp covers the entire wall of the aorta completely. The AVR was approached through the aortic oblique incision just distal to the coronary ostia and

Parameters	Case 1	Case 2	Case 3	Case 4
Age/Sex	39/Female	55/Male	26/Male	26/Male
Presenting complaints	H/o Syncope since 1 year.	H/o dyspnoea on exertion since 6-7 years	H/o chest pain and dyspnoea on exertion for 2 years	H/o dyspnoea on exertion since two months
Co-morbidities	Nil	Hypertension, chronic kidney disease and hypothyroidism since 3 years	Hypertension, Takayasu arteritis and chronic kidney disease since 3 years	Recently diagnosed coarctation of aorta and ASD since 2 months
Physical examination and vitals	Within normal limits	NIBP- 160/100 mmHg		NIBP-160/90 mmHg in left upper limb and 120/60 mmHg in left lower limb
Systemic examination	S1S2+ along with a systolic murmur over right sternal border at second intercostal space	S1S2+ along with a diastolic murmur over right sternal border at second intercostal space	S1S2+ along with a diastolic murmur over right sternal border at second intercostal space	S1S2+ and no murmur
Airway examination	WNL	Mallampatti grade III, two and half fingers mouth opening and buck teeth	WNL	WNL
Blood investigations	WNL	WNL	Serum creatinine - 1.2	WNL
Chest X-ray	WNL	Left Ventricular Hypertrophy (LVH)	LVH	WNL
Electrocardiogram	LVH with strain pattern	LVH with strain pattern	LVH with strain pattern	Sinus rhythm
Other specific investigations	Nil	Nil	DTPA scan- suggestive of negligible left kidney function and mildly reduced right kidney function	Nil
Pre-op 2D Echo	Abdominal aorta-20 mm, ascending aorta-36 mm, e/o Right Ventricular (RV) dysfunction (TAPSE -13 mm), severely depressed Left Ventricular (LV) systolic function, e/o bicuspid Aortic valve (AV), PG/MG across AV - 55/41 mmHg, mild Aortic Regurgitation (AR), moderate Pulmonary Hypertension (PH).	Aortic root-60 mm, ascending aorta - 62 mm, type 1 diastolic dysfunction, aortic sclerosis, severe AR, aortic valve enlarged and tricuspid f/s/o ascending aorta aneurysm, PASP by TR jet - 45 mmHg.	Generalised LV hypokinesia, LVEF- 40%, ascending aorta - 50 mm, type 1 diastolic dysfunction, severe AR with aortic root and ascending aorta dilatation. Mild Mitral Regurgitation (MR), severe Tricuspid regurgitation (TR) with moderately depressed LV systolic function	LVEF-60%, Interatrial septum e/o 9 mm OS-ASD with left to right shunt, mild TR, mild PH, concentric LVH, s/o coarctation of aorta with no obvious gradient across descending thoracic aorta and dampening of flow in abdominal aorta.
Angiography	WNL	Triple vessel disease involving Left Anterior Descending artery (LAD), Left Circumflex Artery (LCX) and Right Coronary Artery (RCA).	WNL	WNL
CT Aortogram	Bicuspid AV with fusiform dilatation of ascending and arch of aorta.	Cardiomegaly with fusiform dilatation of ascending aorta (6.8x6.4cm). Few calcific plaques and an atherosclerotic ulcer in the left lateral wall of arch of aorta.	An ectatic ascending aorta, arch of aorta, descending thoracic and suprarenal thoracic aorta with kinking in thoracic and abdominal region. Cardiomegaly with dilated RA, RV, LV.	A severe focal reduction in the calibre of descending aorta distal to the origin of Subclavian Artery (SCA) s/o postductal coarctation of aorta with multiple collaterals seen around the stenosis.

**[Table/Fig-3]:** Tabular representation of complete history and preoperative investigations of all four cases.

OSASD: Ostium secundum atrial septal defect; PG: Pulmonary gradient; MG: Mitral gradient; TAPSE: Tricuspid annular plane systolic excursion; WNL: Within normal limits; NIBP: Non invasive blood pressure; PASP: Pulmonary artery systolic pressure; LVEF: Left ventricular ejection fraction; LVH: Left ventricular hypertrophy; DTPA: Diethylenetriamine pentaacetate; ECHO: Echocardiogram; e/o: Evidence of; s/o: Site of

followed-up by aortoplasty/prosthetic graft replacement and then simultaneously CABG and valve repair was done. During rewarming, Inj. Nitroglycerine infusion was started at 0.3 µg/kg/min in all patients as it reduces the preload, protects myocardium against ischaemic injuries and facilitates heparin neutralisation in coronary artery bypass surgeries.

After rewarming, de-airing was done by valsalva manoeuvre and providing head-low position. On achieving sinus rhythm, separation from CPB was initiated and ACT was kept below 120 seconds by giving Inj. Protamine and fresh frozen plasma to help in achieving haemostasis. Heart rate, rhythm and Mean Arterial Pressure (MAP) was maintained in all patients and transferred to Intensive Care Unit (ICU) for further weaning and management. The patients were discharged from the ICU on the 3<sup>rd</sup> or 4<sup>th</sup> postoperative day and discharged successfully from the hospital by 10<sup>th</sup> day.

## DISCUSSION

Thoracic aortic diseases can be of various types, namely, aneurysm, dissection, tear and coarctation. Congenital presentation occurs in the infancy and early childhood due to connective tissue diseases like Marfan syndrome, Turner's syndrome and polycystic kidney disease. An acquired presentation is mostly due to atherosclerosis, hypertension and inflammatory changes. The indications for the surgery depend on the predicted surgical risks over the risks of medical management. The immediate surgical intervention is necessitated by factors like aneurysmal size >6.5 cm or 6 cm with connective tissue disease, aneurysmal growth >1 cm/year, rupture/acute dissection and symptomatic patients [6]. These surgeries are generally associated with high mortality and morbidity with significant perioperative complications like arterial hypertension, cerebral aneurysms, aortic aneurysms, IHD and recoarctation [7]. However, the surgical results have improved significantly over time. While the replacement of the aorta with a prosthetic vascular graft is the most common procedure, the aortoplasty, with or without AVR, is an alternative with advantages, namely, less bleeding, shorter CPB and cross-clamp time and lower morbidity and mortality rates [8].

Hence, these complex surgeries require thorough and patient adjusted preoperative evaluation, initiation and maintenance of CPB, neuroprotective strategies, stringent perioperative monitoring and management of complications [9]. A thorough preoperative evaluation including functional capacity assessment, risk stratification for each organ's prediction of postoperative complications and documentation of neurological status is imminent but, can be modified as per the haemodynamic status of the patient and urgency of the surgery. Attention must be given to the cardiac, respiratory, renal and neurological functional status of the patient. Assessment for coronary artery disease must be evaluated simultaneously during the preoperative stage [6]. Preoperative preparation of patients involve cessation of smoking and alcohol consumption, ensuring adequate hydration, strict control of hypertension, optimisation of lipid profile with lifestyle and diet modifications, weight reduction and medical management for risk reduction with beta blockers, Angiotensinogen Converting Enzyme (ACE) inhibitors, Angiotensin Receptor Blockers (ARBs) and statins [2]. Adequate fluid hydration on the day before surgery and hypothermia protection is necessary to prevent the risk of renal failure. Anaesthetic management should be individualised as per the haemodynamic status of the patient, co-morbidities status, nature of surgery and the type of disease. Brain protection strategies are necessary in thoracic aorta surgeries to prevent stroke and preserve cognitive function, which can be ensured by CPB with hypothermia alone (DHCA) direct ante-grade cerebral perfusion of one or more of brachiocephalic arteries (ACP), or retrograde cerebral perfusion via superior venacava (RCP) [2]. The cannulation is done via different approaches based on the pathology and outcomes, namely, direct aortic, femoral, subclavian

and axillary approaches [9]. In the institute, full CPB with DHCA at 16-20°C is the method of choice for the most surgeries involving aorta, as there are no additional cannulas, less risk of intimal injury or embolisation, clear surgical field and technical or perfusion difficulties. Transoesophageal echocardiography, cerebral oxygenation monitoring and neurophysiological monitoring are recommended in almost all procedures, unless contraindicated [2]. These patients are at risk of developing neurological complications which can be due to cerebral hypoperfusion, cerebral embolism and inflammatory reactions. Neuromonitoring is necessary to prevent or detect these complications early to stop the progression. Near Infrared Spectroscopy (NIRS) is a non invasive method of measuring cerebral tissue oxygen saturation in the frontal area. Even, transcranial doppler is a non invasive method to monitor cerebral blood flow velocity and detect emboli. Epi-aortic echocardiography can be used as an allied monitoring technique to prevent or minimise cerebral injury [10]. Other routine measures like, neutral head position, maintaining PaCO<sub>2</sub> above 40 mmHg, MAP >60 mmHg, maintenance of pump flow to 2.5 L/m<sup>2</sup>/min, haematocrit of above 20%, and deeper plane of anaesthesia [10]. Perioperative bleeding/coagulopathy is one of the commonest complications associated with the aortic surgeries. The coagulation factors undergo drastic changes in the surgery, like, activation and consumption of thrombin in CPB and activation of intrinsic coagulation pathway as well as platelets by the exposed collagen [11]. It is essential to ensure adequate haemostasis by administration of anti-fibrinolytics, usage of protamine to reverse the residual effects of heparin, and blood products like fresh frozen plasma, cryoprecipitate and platelets using the point-of-care tests. Instead, prothrombin concentrate complex or rVIIa can be considered in ongoing bleeding.

The main goal of anaesthetic management was to maintain the cardiovascular stability, avoiding hypertension and tachycardia, as the perioperative period is characterised by dramatic fluctuations in the blood pressure [12]. It is necessary to maintain MAP >45 mmHg distal to clamp, normocarbida, normoglycaemia, mild to moderate hypothermia and minimising the cross clamp time (<30 minutes) to ensure the spinal cord and cerebral perfusion. Adequate analgesia and stringent blood pressure maintenance are ensured to prevent hypertensive events in the postoperative stage, which is usually seen in 17-50% of patients [12,13].

## CONCLUSION(S)

The thoracic aortic diseases are frequently associated with high perioperative mortality and morbidity. Vigilant perioperative anaesthetic management along with meticulous surgical care is necessary to improve the prognosis. Special care needs to be given for cardiac and neurological protection, and postoperative surveillance.

## REFERENCES

- [1] Clouse WD, Hallett JW Jr., Schaff HV, Gayari MM, Ilstrup DM, Melton LJ 3rd. Improved prognosis of thoracic aortic aneurysms: a population-based study. *JAMA*. 1998;280:1926-29.
- [2] Erbel R, Aboyans V, Boileau C, Bossone E, Bartolomeo RD, Eggebrecht H, et al. ESC Committee for Practice Guidelines. 2014 ESC Guidelines on the diagnosis and treatment of aortic diseases: Document covering acute and chronic aortic diseases of the thoracic and abdominal aorta of the adult. The Task Force for the Diagnosis and Treatment of Aortic Diseases of the European Society of Cardiology (ESC). *Eur Heart J*. 2014;35(41):2873-926.
- [3] Braverman AC, Guven H, Beardslee MA, Makan M, Kates AM, Moon MR. The bicuspid aortic valve. *Curr Probl Cardiol*. 2005;30:470-522.
- [4] Gargiulo G, Pace Napoleone C, Angeli E, Oppido G. Neonatal coarctation repair using extended end-to-end anastomosis. *Multimed Man Cardiothorac Surg*. 2008;2008(328):mmcts.2007.002691.
- [5] Gill M, Dunning J. Is reduction aortoplasty (with or without external wrap) an acceptable alternative to replacement of the dilated ascending aorta? *Interact Cardiovasc Thora Surg*. 2009;9(4):693-97.

- [6] Agarwal S, Kendall J, Quarterman C. Perioperative management of thoracic and thoracoabdominal aneurysms. *BJA Education*. 2019;19(4):119-25.
- [7] Kozyrev IA, Kotin NA, Averkin II, Ivanov AA, Latypov AA, Gordeev ML, et al. Modified technique for coarctation of aorta with hypoplastic distal aortic arch. *J Card Surg*. 2021;36(6):2063-69.
- [8] Na KJ, Kim JS, Park KH, Lim C. Wrapping of an ascending aortic aneurysm with the multiple boot-straps technique in a patient undergoing off-pump coronary artery bypass grafting. *Korean J Thorac Cardiovasc Surg*. 2015;48(3):206-09.
- [9] Peterss S, Pichlmaier M, Curtis A, Luehr M, Born F, Hagl C. Patient management in aortic arch surgery. *Eur J Cardiothorac Surg*. 2017;51:i4-i14.
- [10] Bashir M, Shaw M, Desmond M, Kuduvali M, Field M, Oo A. Cerebral protection in hemi-aortic arch surgery. *Ann Cardiothorac Surg*. 2013;2(2):239-44.
- [11] Li J, Guan X, Liu O, Wang X, Liu Y, Li H, et al. Changes in coagulation factor XII and its function during aortic arch surgery for acute aortic dissection-a prospective observational study. *J Thorac Dis*. 2018;10(7):4006-16.
- [12] Grewal J. Coarctation of the aorta. *Anaesthesia Tutorial of the Week*. 2012;265.
- [13] Yao F-SF, Hemmings HC, Malhotra V, Fong J, Artusio JF. Yao & Artusio's *Anesthesiology: Problem-oriented Patient Management*. 9th ed. Philadelphia: Lippincott Williams & Wilkins; 2021.

**PARTICULARS OF CONTRIBUTORS:**

1. Senior Resident, Department of Anaesthesiology and Critical Care, TNMC & BYL Nair Hospital, Mumbai, Maharashtra, India.
2. Senior Resident, Department of Anaesthesiology and Critical Care, TNMC & BYL Nair Hospital, Mumbai, Maharashtra, India.
3. Associate Professor, Department of Anaesthesiology and Critical Care, TNMC & BYL Nair Hospital, Mumbai, Maharashtra, India.
4. Professor and Head, Department of Anaesthesiology and Critical Care, TNMC & BYL Nair Hospital, Mumbai, Maharashtra, India.

**NAME, ADDRESS, E-MAIL ID OF THE CORRESPONDING AUTHOR:**

S Ajanth,  
No 230, 7<sup>th</sup> Block, Mogappair West, JJ Nagar West,  
Chennai 37, Mumbai, Maharashtra, India.  
E-mail: ajanves94@gmail.com

**PLAGIARISM CHECKING METHODS:** [Jain H et al.]

- Plagiarism X-checker: Oct 01, 2022
- Manual Googling: Jan 19, 2023
- iThenticate Software: Feb 28, 2023 (11%)

**ETYMOLOGY:** Author Origin**AUTHOR DECLARATION:**

- Financial or Other Competing Interests: None
- Was informed consent obtained from the subjects involved in the study? Yes
- For any images presented appropriate consent has been obtained from the subjects. Yes

Date of Submission: **Sep 23, 2022**Date of Peer Review: **Dec 23, 2022**Date of Acceptance: **Mar 01, 2023**Date of Publishing: **Jun 01, 2023**